

See discussions, stats, and author profiles for this publication at: <https://www.researchgate.net/publication/362182999>

Less invasive O-arm navigation-guided excision of thoracic extraosseous intraforaminal osteoblastoma: A case report

Article in *Surgical Neurology International* · June 2022

DOI: 10.25259/SNI_467_2022

CITATION

1

READS

5

4 authors, including:



Siddharth Katkade
Sancheti Group

6 PUBLICATIONS 2 CITATIONS

[SEE PROFILE](#)



Pramod Bhilare
Sancheti Group

11 PUBLICATIONS 9 CITATIONS

[SEE PROFILE](#)



Case Report

Less invasive O-arm navigation-guided excision of thoracic extraosseous intraforaminal osteoblastoma: A case report

Shailesh Ramakant Hadgaonkar¹, Siddharth Manik Katkade¹, Pramod Dashrath Bhilare¹, Parag Kantilal Sancheti²

Departments of ¹Spine, ²Orthopaedics, Sancheti Institute of Orthopaedics and Rehabilitation, Pune, Maharashtra, India.

E-mail: Shailesh Ramakant Hadgaonkar - drshadgaonkar@gmail.com; *Siddharth Manik Katkade - siddharthkatkade@gmail.com; Pramod Dashrath Bhilare - pramod.bhilare@gmail.com; Parag Kantilal Sancheti - siorresearch1@gmail.com



*Corresponding author:

Siddharth Manik Katkade,
Department of Spine, Sancheti
Institute of Orthopaedics
and Rehabilitation, Pune,
Maharashtra, India.

siddharthkatkade@gmail.com

Received : 15 May 2022

Accepted : 04 June 2022

Published : 23 June 2022

DOI

10.25259/SNI_467_2022

Quick Response Code:



ABSTRACT

Background: Gross-total excision of spinal osteoblastomas remains challenging as they are typically found in close proximity to major neural and/or vascular structures. Here, we found that O-arm navigation allowed for safe/effective excision of a spinal osteoblastoma in a 29-year-old male.

Case Description: A 29-year-old male presented neurologically intact with mid back pain of 8 months' duration and 2 months of the left-sided chest wall discomfort. X-rays showed a sclerotic left D12 pedicle, while the MRI revealed an extradural lesion in extending into the left D11-12 neural foramen (i.e., hypointense on both T1- and T2-weighted images). The CT scan suggested a "floating" foraminal radiolucent lesion with surrounding vertebral body/posterior elements sclerosis and dense peripheral rim enhancement. These findings were diagnostic for an osteoblastoma. Utilizing O-arm navigation, the nidus and full extent of the lesion were excised (i.e., utilizing intralaminar curettage). Two year's postoperatively, there was no MR evidence of tumor recurrence.

Conclusion: O-arm navigation provided accurate intraoperative localization to safely and fully excise a left D11-D12 spinal osteoblastoma.

Keywords: Accuracy, O-arm navigation, Safety, Spinal osteoblastoma, Various operative modalities

INTRODUCTION

About 40% of all osteoblastomas are found in the spine. They mostly involve the posterior spinal elements and occur in, in descending order, the cervical, lumbar, and thoracic regions.^[5] Although MR studies are often equivocal, CT examinations document the lytic/calcified nidus surrounded by a sclerotic rim, classical for osteoblastomas. Here, a 29-year-old male with a left-sided D11/D12 osteoblastoma underwent O-arm localization and safe marginal intralaminar nidus resection.

CASE DESCRIPTION

A 29-year-old male presented with 8 months of mid back pain and 2 months of the left-sided chest wall discomfort with VAS 8/10. His examination revealed diffuse mid back tenderness but no neurological deficit. X-rays showed a mixed sclerotic/lytic lesion involving the left D12 pedicle and superior articular process [Figures 1a and b]. The MRI showed an extradural left-sided D11-12 foraminal lesion. It also involved the superior articular process and left pedicle of D12

This is an open-access article distributed under the terms of the Creative Commons Attribution-Non Commercial-Share Alike 4.0 License, which allows others to remix, transform, and build upon the work non-commercially, as long as the author is credited and the new creations are licensed under the identical terms.

©2022 Published by Scientific Scholar on behalf of Surgical Neurology International

Table 1: Highlighting different surgical modalities available to treat spinal osteoblastoma with their merits and demerits.

S. No.	Literature	Author	Merits	Demerits
1.	Percutaneous CT-guided resection	Assoun <i>et al.</i>	Complete excision of nidus and with no recurrence seen in nonspinal osteoblastoma.	High failure rate, scattering of metal instruments, difficulty in accurately localizing the drill tip, accidental dural and spinal cord injury.
2.	Percutaneous laser photocoagulation under CT guidance	Gangi <i>et al.</i>	18-gauge to maximum 14-gauge needle with high degree of precision. The procedure is performed under neuroleptanalgesia and requires only overnight hospitalization.	Do not permit histologic confirmation, so it is not indicated in any doubtful lesions. Heating the tip of a needle to 90°C for 4–6 min in a nidus situated adjacent to neural structures inevitably risks thermal damage to the neural structures.
3.	Video-assisted thoracoscopic surgery (VATS)	Campos <i>et al.</i>	Accuracy and completeness of VATS is comparable with open with advantages of minimal invasive technique.	Steep learning curve, keeping up with evolving surgical technique and instrumentation, and higher costs.
4.	2D versus 3D fluoroscopy-guided open excision	Kadhim <i>et al.</i>	Safe and effective localization was achieved by intraoperative O-arm guidance followed by intraoperative confirmatory CT scan.	The C-arm failed to identify the tumor in one case and needed transport to perform a CT scan.
5.	3D navigation-guided excision	Rajasekaran <i>et al.</i>	Accuracy, precision with real-time imaging and intraoperative CT confirmation of complete extirpation of tumor.	Radiation exposure and high-cost factor.

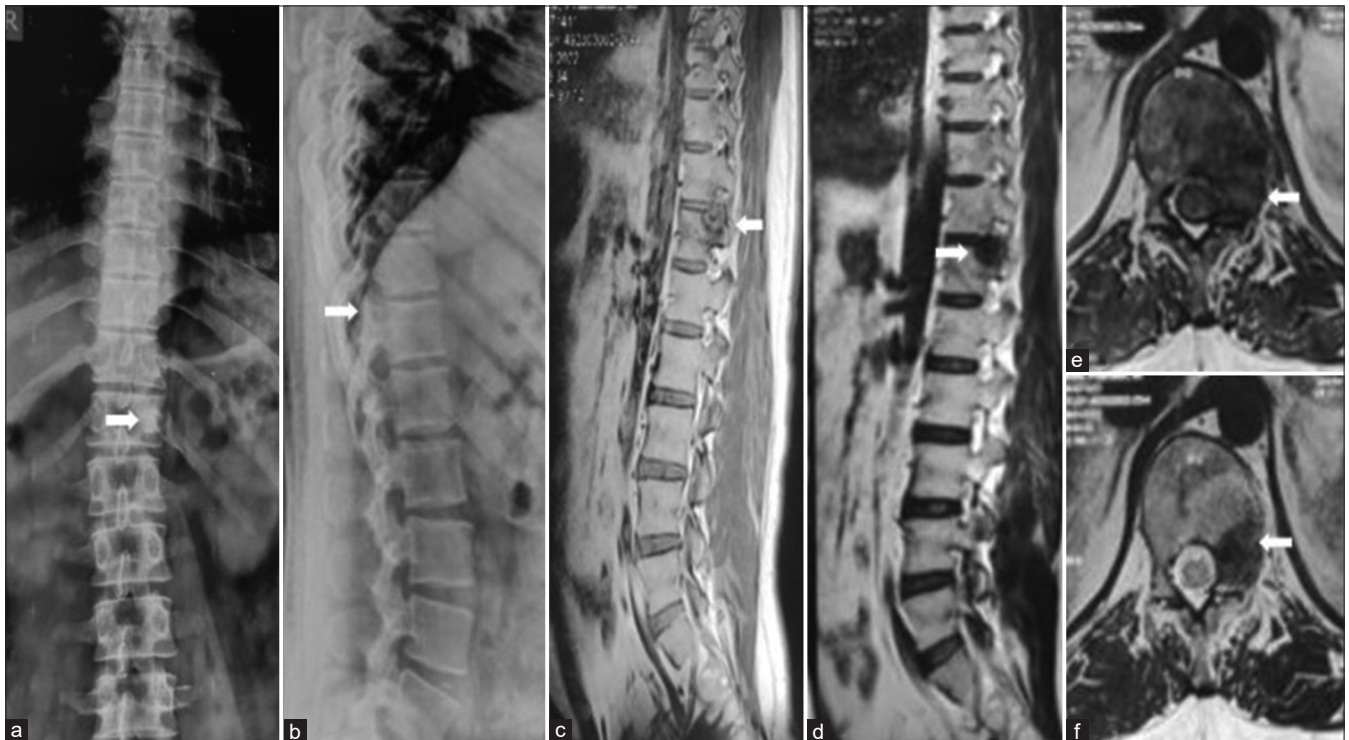

Figure 1: X-ray and MRI images; (a) AP view showing sclerosis of the left D12 pedicle, (b) lateral view showing radiolucent shadow in D12 superior articular process along, (c) sagittal T1WI showing hypointense lesion surrounded by isointense shadow, (d) sagittal T2WI showing hypointense shadow obliterating foramen, and (e) axial T1WI and (f): axial T2WI showing involvement of pedicle and part of endplate (white arrows).

(i.e., hypointense on both T1WI and T2WI) [Figures 1c-f]. The CT scan showed; a floating foraminal radiolucent lesion, pedicular cortical ballooning, and breach with posterior element sclerosis plus peridiscal osteophytes. The enhanced study revealed a peripheral dense rim enhancement involving the superior articular process and superior end plate of D12 [Figures 2a-c]. These findings were consistent with the diagnosis of an osteoblastoma.

Surgery

Using O-arm navigation, the tumor was entirely excised (i.e., including the tumor nidus and intralesional curettage) and followed by a standard posterior midline pedicle/screw/rod instrumented fusion from D11 to L1 level [Figures 3a-d, 4a]. The patient was mobilized the next day, and gradually, his back pain improved to 3/10 on the VAS scale. The histopathological evaluation confirmed the diagnosis of an osteoblastoma [Figure 4b]. The latest 2-year postoperative follow-up revealed that the patient was asymptomatic without tumor recurrent on the CT scan [Figures 4c-f].

DISCUSSION

Frequency and location of osteoblastomas

Osteoblastomas constitute 1% of all bone tumors, with 40% localized to the spine. They are typically located in posterior elements, in descending order, of the cervical, lumbar, thoracic spine, and only rarely the sacrococcygeal levels. About 80% of osteoblastomas occur in patients under 30 years of age and are predominantly found in males (i.e., male-to-female ratio of 2.5:1). The pain associated with osteoblastomas is somewhat less robust with NSAIDs/aspirin versus osteoid osteomas (i.e., defined as < 1.0 cm).^[5]

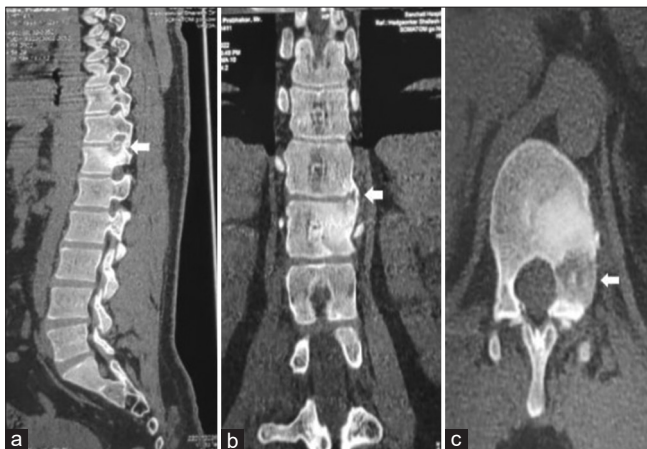

Figure 2: CT images; (a) sagittal image showing floating foraminal nidus, (b) coronal image showing peridiscal osteophyte, and (c) axial image showing thinned out ballooned cortex (white arrows).

Two presentations: Conventional versus aggressive

There are two types of osteoblastomas; conventional and aggressive.^[10] Conventional lesions are typically localized within the osseous spinal structures, often demonstrating a lytic occasionally calcified nidus with a sclerotic rim best seen on CT scan.^[10] Aggressive tumors are equal to or >1.5 cm and present almost a year earlier than conventional osteoblastomas. Radiographically, they are predominantly lytic lesions that often extend into the paravertebral soft tissues and epidural space. Patients who present with neurological deficits require radical tumor excision to avoid recurrence.

Surgical recommendations for osteoblastomas

The total excision of osteoblastomas is recommended as they have a 50% recurrent rate with partial/subtotal excision.^[5] Marginal *en bloc* resection with intralesional excision of the nidus is the mainstay of treatment, as performed in this case. Multiple advanced technologies have been utilized to facilitate intraoperative localization and safer resection of osteoblastomas [Table 1]. They include radionuclide localization using gamma probe,^[9] intraoperative CT-guided localization,^[1,3,4] and computer navigation-aided localization.^[6,7] Percutaneous CT-guided laser photocoagulation and thermal ablation have been used.^[3]

Rajasekaran *et al.* used of fluoroscopy-based computer navigation in four cases of osteoid osteoma.^[7]

Campos *et al.* used O-arm navigation in video-assisted thoracoscopic surgery for resection of osteoid osteoma in dorsal vertebra.^[2] Mori *et al.* successfully treated two cases of osteoid osteoma located adjacent to facet joint by navigation-

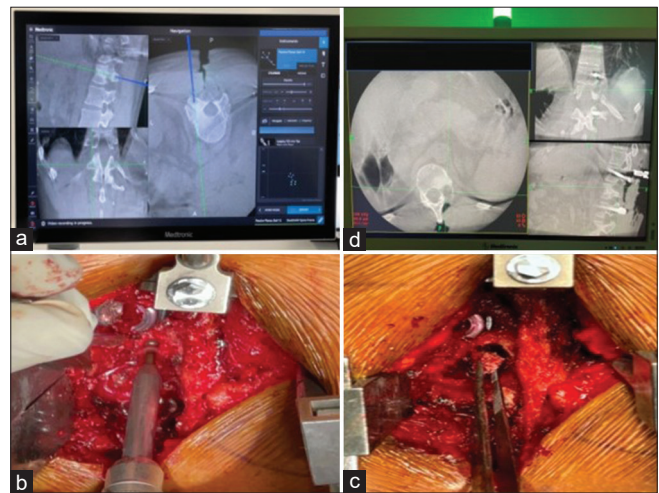


Figure 3: Intraoperative navigation and clinical images; (a) navigation-guided exact location of nidus, (b) burring superior articular process of D12, (c) excised nidus, and (d) postoperative O-arm 3D CT confirming complete excision of tumor.

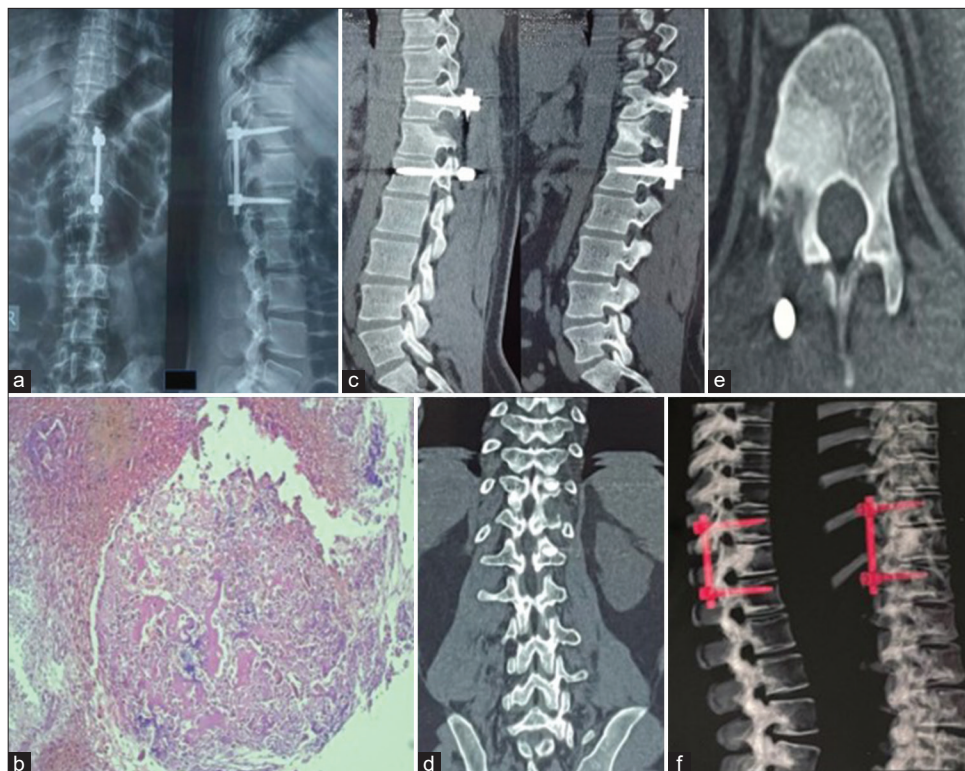


Figure 4: (a) Postoperative X-ray showing absent nidus and proper implantation, (b) histopathological slide showing a neoplasm composed of interanastomosing trabeculae of woven bone lined by a single layer of osteoblast set within loose edematous fibrovascular stroma with no evidence of increase mitosis or necrosis consistent with osteoblastoma, and (c-f) 2 years postoperative CT images showing no signs of recurrence.

guided high-speed drill through a translaminar tunnel to reach the nidus.^[6] The high cost of O-arm navigation and radiation exposure is the shortcomings of this technique (i.e., the radiation produced by an O-arm is comparable to a CT scan or a prolong use of C-arm). A low-dose protocol (as used here) can reduce the radiation nearly to half (CT chest O-arm standard dose – 2.99 mSv and low dose – 1.88 mSv).^[8]

CONCLUSION

O-arm navigation aids accurate location of spinal osteoblastoma and helps to target the nidus resulting in it's safe and complete excision with intraoperative confirmatory CT scan avoiding neural damage, minimizing dissection, bone removal, and blood loss resulting in faster recovery.

Declaration of patient consent

The authors certify that they have obtained all appropriate patient consent.

Financial support and sponsorship

Publication of this article was made possible by the James I. and Carolyn R. Ausman Educational Foundation.

Conflicts of interest

There are no conflicts of interest.

REFERENCES

1. Assoun J, Railhac JJ, Bonneville P, Poey C, de Gauzy JS, Baunin C, *et al.* Osteoid osteoma: Percutaneous resection with CT guidance. *Radiology* 1993;188:541-7.
2. Campos WK, Gasbarrini A, Boriani S. Case report: Curetting osteoid osteoma of the spine using combined video-assisted thoracoscopic surgery and navigation. *Clin Orthop Relat Res* 2013;471:680-5.
3. Gangi A, Dietemann JL, Guth S, Vinclair L, Sibia J, Mortazavi R, *et al.* Percutaneous laser photocoagulation of spinal osteoid osteomas under CT guidance. *AJNR Am J Neuroradiol* 1998;19:1955-8.
4. Kadhim M, Binitie O, O'Toole P, Grigoriou E, De Mattos CB, Dormans JP. Surgical resection of osteoid osteoma and osteoblastoma of the spine. *J Pediatr Orthop B* 2017;26:362-9.
5. Limaieem F, Byerly DW, Singh R. *Osteoblastoma*. Treasure Island, FL: Stat Pearls Publishing; 2022.
6. Mori K, Neo M, Takemoto M, Nishizawa K, Imai S. Navigated pin-point approach to osteoid osteoma adjacent to the facet joint of spine. *Asian Spine J* 2016;10:158-63.
7. Rajasekaran S, Kamath V, Shetty AP. *Intraoperative Iso-C*

three-dimensional navigation in excision of spinal osteoid osteomas. *Spine (Phila Pa 1976)* 2008;33:E25-9.

8. Su AW, Luo TD, McIntosh AL, Schueler BA, Winkler JA, Stans AA, *et al.* Switching to a pediatric dose O-arm protocol in spine surgery significantly reduced patient radiation exposure. *J Pediatr Orthop* 2016;36:621-6.
9. Wioland M, Sergent-Alaoui A. Didactic review of 175 radionuclide-guided excisions of osteoid osteomas. *Eur J Nucl Med* 1996;23:1003-11.
10. Yin H, Zhou W, Yu H, Li B, Zhang D, Wu Z, *et al.* Clinical characteristics and treatment options for two types of osteoblastoma in the mobile spine: A retrospective study of 32 cases and outcomes. *Eur Spine J* 2014;23:411-6.

How to cite this article: Hadgaonkar SR, Katkade SM, Bhilare PD, Sancheti PK. Less invasive O-arm navigation-guided excision of thoracic extraosseous intraforaminal osteoblastoma: A case report. *Surg Neurol Int* 2022;13:263.